*Online Journal of Health and Allied Sciences*
Peer Reviewed, Open Access, Free Online Journal
Published Quarterly : Mangalore, South India : ISSN 0972-5997
Volume 14, Issue 2; Apr-Jun 2015



*Short Report:*

# A Novel Technique to Prevent Effluent Spillage During Percutaneous Cystolithotripsy.

**Authors**
**Sunil P Shenoy,** Professor & Head,
**Pritam Sharma,** Assistant Professor,
**Prashanth K Marla,**Associate Professor,
**Chandu Krishna Batchu,** Senior Resident,
**Department of Urology, A J Institute of Medical Sciences, Mangalore - 575004, Karnataka, India.**

**Address for Correspondence**
**Dr Sunil P Shenoy,**
Professor & Head, Department of Urology
A J Institute of Medical Sciences,
Mangalore - 575004,
Karnataka, India.

**E-mail:** drsunilpshenoy@gmail.com

**Citation**
Shenoy SP, Sharma P, Marla PK, Batchu CK. A Novel Technique to Prevent Effluent Spillage During Percutaneous Cystolithotripsy. *Online J Health Allied Scs.* 2015;14(2):4. Available at URL: http://www.ojhas.org/issue54/2015-2-4.html

**Open Access Archives**
http://cogprints.org/view/subjects/OJHAS.html
http://openmed.nic.in/view/subjects/ojhas.html

Submitted: May 20, 2015; Accepted: Jun 28, 2015; Published: July 15, 2015

**Abstract:** Our objective was to design an efficient system for collection of refluxing irrigant during performance of percutaneous cystolithotripsy (PCL) to avoid the messy spillage and its undesirable consequences on the patient, the operating team and the operating room environment. A closed drainage system using a long sleeve surgical glove, 10 millimeter laparoscopic trocar, 30 french Amplatz sheath, Y-tubing and linen thread was designed for performing PCL without disconnection during the procedure. While the refluxing effluent was efficiently drained, minimizing spillage, the calculus fragments were collected in a distensible receptacle adjacent to the Amplatz sheath. Three procedures were performed over a year on males with large bladder calculi. The system designed by us was easy to set up, lent itself to easy unhindered performance of the procedure, and spillage of effluent was minimized.
**Key Words:** Amplatz sheath, Percutaneous Cystolithotripsy, Trocar, Vesical calculus.

**Introduction:**
Cystolithotripsy (CLT) for large bladder calculi is laborious, time-consuming, and runs the risk of urethral injury in males due to prolonged, large caliber and manipulative instrumentation. Percutaneous cystolithotripsy (PCL) offers a safe and effective alternative.(1,2) A disadvantage of PCL that has not been reported is the extensive soakage of the patient drapes, contamination of the operating table, the operating room (OR) floor and the operating team during the procedure. The centrally placed lower abdominal PCL access poses a technical problem for effective collection of effluent. We herein describe a simple, indigenously designed system to address this problem.

**Case Report and Results**
During the period from January 2014 to January 2015, we treated three male patients with giant bladder stones (larger than 4 cms in diameter) by PCL using our custom-designed effluent collecting system. All patients gave informed consent for PCL. The volume of refluxed saline irrigant collected was measured against the volume of irrigant instilled (Table 1).No diuretics were used during any of the procedures.
The armamentarium included a long sleeved surgical glove, a 30 French PCNL Amplatz sheath (Amplatz), the trocar of a 10 mm laparoscopic cannula and a Y-tube irrigation tubing set (Figure 1A). The trocar coupled perfectly with the Amplatz sheath (Figure 1B). One of the glove fingers served as a sheath around the Amplatz. The limbs of the Y-tube were connected to drain the effluent through two separate glove fingers. The wrist of the glove wrapped around the cysto-nephroscope. Linen thread was used to reinforce all the glove connections to ensure a near water tight system (Figure 1C).
The trocar-Amplatz assembly was pre-inserted through a glove finger from within-without and the tubular finger sleeve retracted to the proximal half of the Amplatz (Figure 1D). Under cystoscopic guidance, the trocar-Amplatz assembly was inserted into the bladder and the Amplatz sheath positioned. The 26 French cysto-nephroscope was inserted through the wrist of the glove and the sleeve fixed to the scope. The Y-tube irrigant entry ends were placed in two separate glove fingers through adequate sized openings created at the tips. The tube tips were positioned a centimeter within the palm of the glove. The common channel of the Y-tube was positioned in a receptacle placed on the floor to collect the effluent.

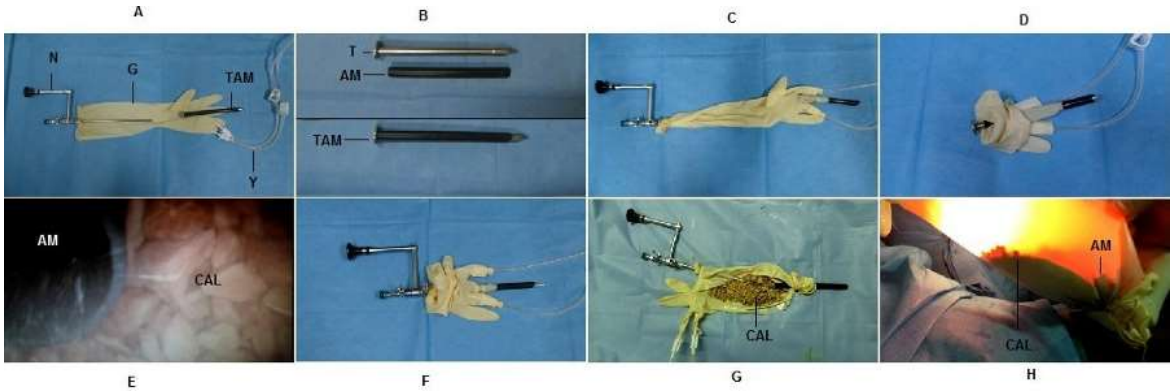


**Figure 1: AM: Amplatz sheath, CAL: Calculi, G: Glove, N: Nephroscope, T: Trocar, TAM: Trocar-Amplatz assembly, Y: Drainage tubing. Figure 1H shows the silhouette of calculi fragments below the level of the Amplatz outlet against the transillumination.**

Fragmentation was performed with the pneumatic lithoclast using a 2 mm probe. Larger fragments were extracted using the alligator or tri-prong forceps and dropped into the palm segment of the glove (Figure 1E).

Smaller fragments were evacuated through a cystoscope using Toomey syringe. A 16 French urethral Foley catheter was placed and the Amplatz sheath removed. The indigenously designed effluent collecting system using easily available surgical materials lent itself to easy assembly and unhindered performance of PCL. Spillage of effluent was minimized. More than 90 percent of the efflux was collected within the closed drainage system (Table 1). Some unavoidable spillage did occur through the operating channel of the cysto-nephroscope and around the Amplatz sheath. Calculus fragments extracted were conveniently dropped in the glove chamber next to the Amplatz, saving time and effort. The receptacle was spacious, distensible and allowed fragments of calculi to settle below the Amplatz outlet. The extracted calculi were prevented from re-entry into the bladder by virtue of the system design. Urethral instrumentation was restricted to the initial cystoscopy and terminal bladder wash.

**Table 1: Observations on collected versus instilled irrigant volumes during the 3 cases of percutaneous lithotripsy using our collecting device.**

| | **Patient 1** | **Patient 2** | **Patient 3** |
|---|---|---|---|
| **Stone size (cm)** | 4.8 | 5.3 | 4.6 |
| **Duration of Procedure (Minutes)** | 155 | 180 | 172 |
| **Instilled irrigant volume IIV (Liters)*** | 26 | 33 | 31 |
| **Collected irrigant volume CIV(Liters)*** | 24 | 30 | 29 |
| **CIV /IIV (%)** | 92.3 | 90.9 | 93.54 |
| *Corrected to the nearest half liter | | | |

## Discussion

While the advantages of PCL over transurethral cystolithotripsy and cystolithotomy for the treatment of large bladder calculi are well documented, we have found no reference in literature to the associated problem of overflow of the voluminous refluxing irrigant with its adverse consequences.(1,2) Hypothermia due to moist patient drapes and contamination of the OR table, floor, and operating team are undesirable effects to be minimized if not avoided. While the former can be prevented by moisture impervious drapes, the latter cannot and requires systems or devices to divert the effluent efficiently. (3) A twin-Amplatz sheath technique of treating large vesical stones in females using a urethral sheath in addition to a percutaneous one does suggest a way to divert the effluent during PCL, but seems impractical in the male wherein one aims at minimizing urethral instrumentation.(4) In addition, a certain optimal degree of bladder filling is necessary to maintain space and vision for fragmentation and this would be difficult with an unhindered drainage per-urethra. In the run-up to designing a collecting device, we considered the use of a urethral Foley catheter with intermittent clamping and release. However, reflux through the supra-pubic Amplatz beside the cysto-nephroscope continued even when the catheter was open, possibly due to the inherent higher resistance in the catheter channel vis-à-vis the supra-pubic outlet. While conceptualizing a device that could efficiently and effectively circumvent the problem, we earmarked certain minimum requirements. It needed to be water tight. It therefore had to necessarily encompass the cysto-nephroscope, the supra-pubic Amplatz sheath and the drainage outlet tubing. It needed enough length and flexibility to allow easy entry and exit of the cysto-nephroscope into the bladder through the entire length of the Amplatz and beyond (Figure 1F). It needed space to deposit the stone fragments without disconnecting any of the junctions (Figure 1G). The Amplatz was required to be free for manipulation in any direction. The drainage had to be efficient. Calculus fragments could not be allowed to get back into the bladder (Figure 1H).

A long sleeved rubber glove served as an ideal receptacle with its inherent capacity, length, ability to distend and flexibility. We assigned the wrist of the glove to the nephroscopic end since this being largest, was obviously the most trying one to ensure water-tightness. Since the cysto-nephroscope is held vertically elevated throughout the procedure, the fluid level in the receptacle never reached the level of this

junction. The 4-5cms projection of the Amplatz sheath into the palm of the glove helped prevent re-entry of fragments into the bladder. The distensile nature and flexibility of the glove ensured that with increasing load of fragments, the floor actually sank lower, thus helping to retain the fragments within. Two drainage channels through individual finger sleeves effectively served to keep the receptacle decompressed. Twisting of the finger-palm junction of the glove causing blockade of drainage was an initial problem that was circumvented by advancing the tube ends for a centimeter beyond this point.

We faced a few technical problems during the procedure. Turbidity of the fluid within the receptacle as the fragmentation progressed lead to difficulty in visual re-entry into the Amplatz. Inserting the scope, with the receptacle empty, occasionally lead to intussusception of the glove into the sheath. Both these problems were easily overcome with help from the assistant. There was minimal peri-Amplatz leak that was continually soaked up with absorbent mops. Some reflux leakage through the instrument channel of the cysto-nephroscope beside the forceps could also not be avoided. Over 90 percent of the total irrigation fluid effluent could be channelized into the drainage system. The undetermined additional urine output, without diuretic usage, was considered likely to be comparable in all three cases, negligible in proportion to the irrigant volumes, and hence not materially influencing the observations. The overall leakage and soiling of the OR area was subjectively less than in our earlier cases before we started using this indigenously designed device.

In conclusion, reflux and overflow of the irrigant through the supra-pubic Amplatz sheath is an undesirable and vexing accompaniment of Percutaneous Lithotripsy. Since PCL is gaining acceptance as the procedure of choice for large bladder calculi, over transurethral lithotripsy and cystolithotomy, it is imperative that this issue gets addressed, in the interest of the patient, the OR environment as well as the operating team. We have described a simple, indigenously designed, cost effective, and replicable solution to avoid this. While our device is far from perfect, it is helpful in limiting the overflow and contamination during PCL and provides an idea to scientifically design user friendly gadgets for the purpose.

**References**


1. Sofer M, Kaver I, Greenstein A et al. Refinements in treatment of large bladder calculi: simultaneous percutaneous suprapubic and transurethral cystolithotripsy. *Urology* 2004 April;64:651-4.
2. Wollin TA, Singal RK, Whelan T et al. Percutaneous suprapubic cystolithotripsy for treatment of large bladder calculi. *J Endourol.* 1999 October;13:739-44.
3. Maglinger PE, Sessler DI, Lenhardt R. Cutaneous Heat Loss with Three Surgical Drapes, One Impervious to Moisture. *Anesth Analg*. 2005 March;100:738-42.
4. Kumar A, Dalela D, Dalela D et al. The Twin Amplatz Sheath Method: A Modified Technique of Percutaneous Cystolithotripsy for Large Bladder Stones in Female Patients. *J Surg Tech Case Rep.* 2013 February;5:109–111.